ADVANCED TRACK

DIABETES AND OTHER HEALTH CONDITIONS

Alexandra Reiher
MD
Centura – St. Anthony's Hospital,
Lakewood CO

EPIC DIABETES CONFERENCE

MAY 22, 2021 | WEBINAR

EMPOWERING PATIENTS FOR INDIVIDUALIZED CARE

Barbara Davis Center for Diabetes • Children's Diabetes Foundation •

CONFLICTS OF INTEREST: NONE

DIABETES AND OTHER HEALTH CONDITIONS

TOPICS:

- Musculoskeletal
- Neurologic/Memory
- Osteoporosis
- Dermatologic Conditions

MUSCULOSKELETAL CONDITIONS:

Hand/Wrist:

- Carpal Tunnel Syndrome (10-20%)
- Dupytren's Contracture (15-45%)
- Trigger Finger

Shoulder:

- Adhesive capsulitis (Frozen Shoulder) (10-30%)
- Rotator cuff tendonopathy
- calcified periarthritis

Limited Joint Mobility Syndrome

Diabetic Amyotrophy

Diabetic Myonecrosis

Stiff Person Syndrome

Image borrowed from www.mayoclinic.org

LIMITED JOINT MOBILITY (CHEIROPATHY)

Associated with poor glycemic control, advanced age, and smoking

Increased risk with duration of diabetes

Affects upper limbs and hands

Thick, rigid, waxy skin

At risk for other microvascular complications

Clinical findings: Prayer Sign, Table Top Sign

Treatment: smoking cessation, improve glycemic control, physical therapy, NSAIDs

DIABETIC MYONECROSIS

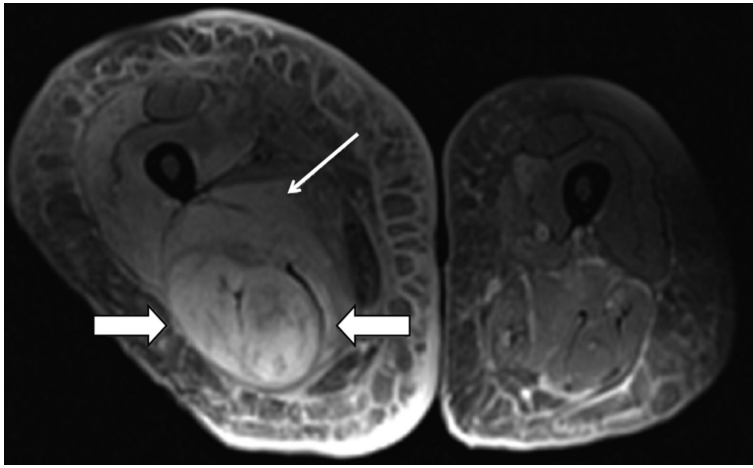

- Spontaneous infarction of muscle, rare disease associated with long-standing diabetes (type 1 and type 2)
- Increased mortality rate due to associated cardiovascular disease
- Present with acute pain and swelling in an extremity
- No prior history of trauma to the affected region
- Markers of inflammation are elevated
- Diagnosed by ultrasound or MRI
- Treatment – symptomatic management, generally self-limiting
  - bedrest, glycemic control, NSAIDs
- Resolves after 6-12 weeks
- Anti-platelet therapy (aspirin) usually prescribed
- Recurrence rate near 50%

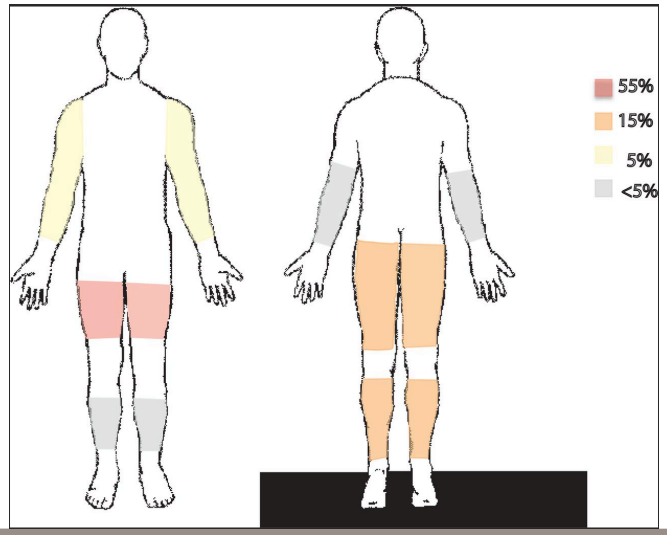

DIABETIC AMYOTROPHY

Diabetic lumbosacral plexopathy

Often in well-controlled or recently diagnosed type 2 diabetes (1% of patients with T2D)

Presentation: acute onset proximal leg pain, muscle weakness, loss of muscle mass

- Starts in one leg, often progresses to involve both legs
- Associated with significant weight loss in 80% of patients

Pathophysiology: ischemic neural injury due to microvasculitis

Self-limited course, most will have some clinical improvement (though rarely 100%)

foot drop, neuropathic pain – can persist for years

Muscular weakness or pain can persist

Treatment: pain relief, supportive management

Limited data to support use of steroids or immunosuppressive therapy

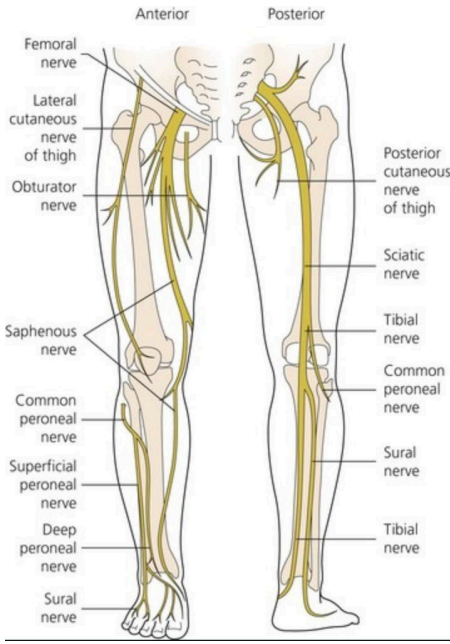

NEUROLOGIC CONDITIONS/MEMORY

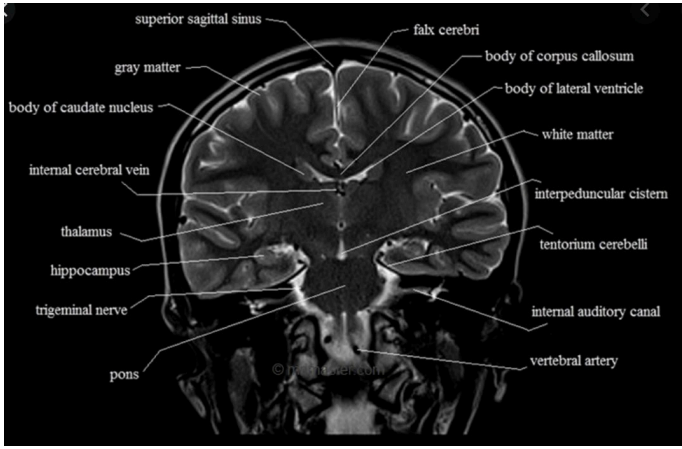

Increased risk of cognitive decline in both T1D and T2D

T2D: Associated with impaired attention, processing and motor speed,

executive functioning, and verbal memory

Younger age at onset of T2D significantly associated with a higher risk of subsequent dementia

Longer duration of diabetes associated with faster cognitive decline

Regarding the metabolic syndrome and cognitive decline: hyperglycemia has the strongest association with risk of developing cognitive impairment

Diabetes is considered a risk factor for both vascular dementia and Alzheimer's disease (AD)

Obesity is also a risk factor for development of dementia

Mechanism not entirely understood

one theory - insulin receptor dysfunction in the brain (including the hippocampus), although not related to circulating insulin levels

increased expression of pro-inflammatory cytokines in the brain in DM – role in neuronal damage

NEUROLOGIC CONDITIONS/MEMORY

In the Diabetes Control and Complications Trial (DCCT) and Epidemiology of Diabetes Interventions Complications (EDIC) Studies:

T1D with higher A1c (>8.8%): moderate declines in motor speed and psychomotor efficiency compared to patients with better glycemic control (A1c <7.4%)

children diagnosed with T1D: greater cognitive impairment present in children diagnosed before age 7 compared to those diagnosed at a later age

NEUROLOGIC CONDITIONS/MEMORY

Prevention?

Small studies have shown improvement in executive function in T2D after 6 months of aerobic intervention, another study showed improvement in verbal memory after exercise and dietary intervention for 6 months

Intensive glycemic control in T2D associated with a slowed rate of brain atrophy on MRI

Medications: GLP1 agonists

- Liraglutide (Victoza) was associated with reduced memory impairment and increased synaptic plasticity in animal models
- Liraglutide and Lixisenatide: both reversed memory impairment, prevented deterioration of synaptic plasticity in the hippocampus, reduced beta-amyloid plaque in the cortex in animal studies

Supplements: anti-oxidants and anti-inflammatory medications

- curcumin, vitamin E – improved learning and memory in animal studies

OSTEOPOROSIS

Increased risk in T1D, appears to be an increased risk in T2D (but less clear)

Increased risk observed after at least 10 years' history of DM
Unclear if glycemic control decreases risk or not

Can be related to increased risk of falling
(if vision loss, neuropathy)
Peripheral neuropathy
associated with increased bone loss
and fracture risk at foot and ankle

Diabetic medications can play a role

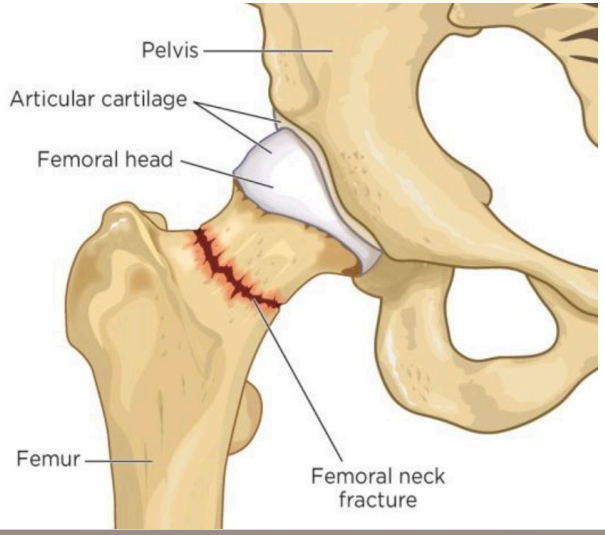

DIABETIC MEDICATIONS AND RISK OF OSTEOPOROSIS/FRACTURES

Medications	Bone Mineral Density	Risk of Fracture
Metformin	=/↑	↓ /=
Sulfonlyureas (ie glipizide)	no data	↓ /=/ ↑
TZD (ie actos/pioglitazone)	↓↓ /=	↑↑ /=
GLP1 agonists (ie Trulicity, Ozempic, Victoza, Rybelsus)	↑ /=	=
DPP4 inhibitors (ie Januvia, Tradjenta, Nesina)	--	↓ /=
SGLT2 inhibitors (**Invokana**, limited data for Steglatro, Farxiga, Jardiance)	=	=/ ↑
Insulin	=	↑

Adapted from Ferrari et al. 2018

DERMATOLOGIC CONDITIONS

- Acanthosis nigricans
- Bullous Diabeticorum
- Diabetic Dermopathy
- Sclerodermiform disorders
- Grannuloma Annulare
- Necrobiosis Lipoidica Diabeticorum
- Diabetic foot ulcerations

ACANTHOSIS NIGRICANS

Skin thickening in fold, particularly armpits
- velvety appearance

Due to hyperinsulinemia

Seen in type 2 diabetes

Can also be associated with skin tags

Associated with the metabolic syndrome in obesity

Typical areas affected: armpits, neck, umbilicus, elbows

Treatment: reducing insulin resistance
- weight loss, exercise, metformin

GRANULOMA ANNULARE (GA)

Benign, self-limiting

Dermatitis of the pretibial regions, extensor surfaces of the limbs

Seen in response to infections, malignancy

Can by seen in patients with diabetes

Women affected more than men

Affected areas - those exposed to trauma

- back of hands and feet, fingers, elbows, arms, legs

Asymptomatic

Occasionally itchy/burning sensation

Possibly due to release of lymphokines, stimulating synthesis and activity of collagenase

Can disappear spontaneously within 2 years

NECROBIOSIS LIPODICA DIABETICORUM (NLD)

Unknown origin

0.3-1.6% of patients with diabetes/year

80% women, Caucasian

Can occur at any age, most often 4th-6th decades

Development is not associated with glycemic control

Degenerative disease of collagen in the dermis and subcutaneous fat with an atrophic epidermis

Typically present on both legs, pretibial region

15% of cases involve other areas – abdomen, upper limbs, scalp

Can be asymptomatic, or associated with burning/itching

If ulcerations develop, can be painful

Spontaneous resolution 10-20% cases

Treatment –

- avoid trauma to the area
- drug treatment – limited effectiveness
- intralesional injection, oral use of corticosteroids
- topical agents if lesion are flat

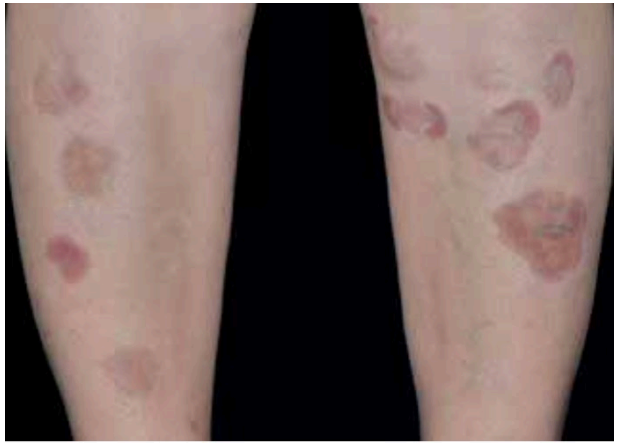

REFERENCES

Signla R, Gupta Y, and Kalra S. Musculoskeletal effects of diabetes mellitus. Recent advances in Endocrinology. 2015;65(9):1024-1027.

Horton WB et al. Diabetic muscle infarction: a systematic review. BMJ Open Diabetes Research and Care 2015;3e000082.

Zilliox LA et al. Diabetes and Cognitive Impairment. Curr Diab Rep 2016;16(9):87.

Amidei CB et al. Association Between Age at Diabetes Onset and Subsequent Risk of Dementia. JAMA 2021;324(16)1640-1649.

Ferrari et al. Diagnosis and management of bone fragility in diabetes: an emerging challenge. Osteoporosis International 2018; 29:2585-2596

Mendes AL, Haddad V, and Miot HA. Diabetes mellitus and the skin. An Bras Dermatol. 2017;92(1):8-20.